
Horizon™ DXA System: Technical and Clinical Advantages

Kevin E. Wilson, PhD

Thomas L. Kelly

Hologic, Inc., Bedford, MA, USA

Introduction

The Horizon™ DXA systems are Hologic's latest generation of bone densitometers and the only densitometers to use ultra-fast, high output ceramic detectors and a high frequency, pulsing x-ray generator. Horizon system's latest digital detector and x-ray technology combine to provide the ability to measure a wide range of clinical patients, including the morbidly obese, with unsurpassed image quality and long-term stability, all in a flexible platform designed for future enhancements.

Horizon DXA systems come packed with new features, including FDA cleared exams (Figure 1) not available from other manufacturers. These features have proven clinical safety and effectiveness, and represent the most comprehensive set of clinical applications available today.



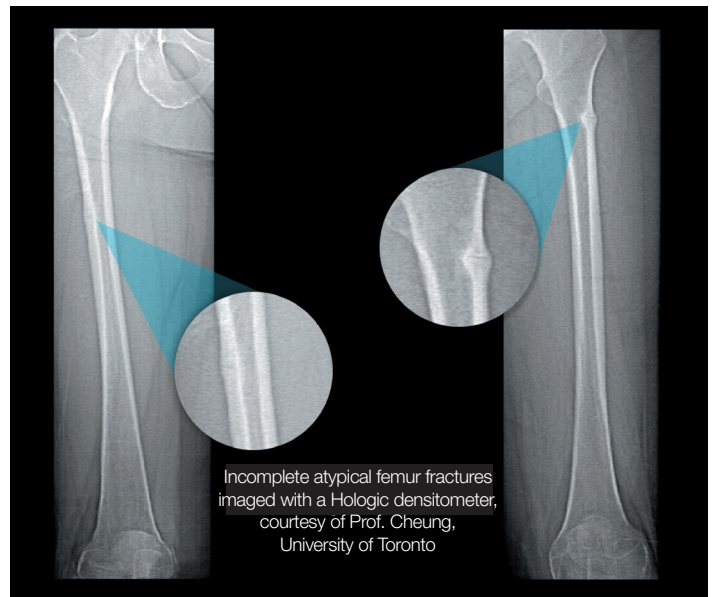
Horizon DXA system

Horizon DXA System Description:

The key technology innovations of the Horizon DXA system includes ceramic detectors, a high frequency, pulsing X-ray generator system, and an internal reference system.

Ceramic detectors have proven their performance in multi-slice CT scanners and are used by all leading CT manufacturers. By adopting this technology, Horizon systems

Figure 1



Incomplete atypical femur fractures imaged with a Hologic densitometer, courtesy of Prof. Cheung, University of Toronto

Single-energy femur exam demonstrating cortical thickening indicates the presence of an incomplete atypical femur fracture (AFF).

benefit from higher signal-to-noise performance, while also eliminating cadmium from the detector system. Cadmium is a restricted hazardous substance and exposure to cadmium has been listed as a major health concern by the World Health Organization¹. Clinically, the effect of the improved signal-to-noise ratio of Horizon system images can be seen on very high BMI patients, where X-ray penetration may have been a problem in the past (Figure 2, 3).

High frequency, pulsing X-ray generators are used in fluoroscopy to reduce dose while maintaining image quality. The newly developed X-ray generator provides enhanced stability and a smaller form factor for improved table access. To maintain data compatibility with the Discovery™ series, the new Horizon system's X-ray generator currently supports all of the Discovery scan modes. However, with the added flexibility of the new X-ray source, Hologic scientists and engineers can bring new applications to market (pending regulatory clearance in local markets).

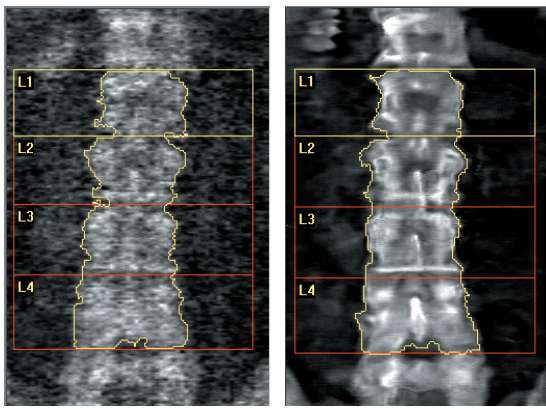


Figure 2

Discovery™ image (left) and Horizon™ system image (right) of an obese subject (BMI=54).

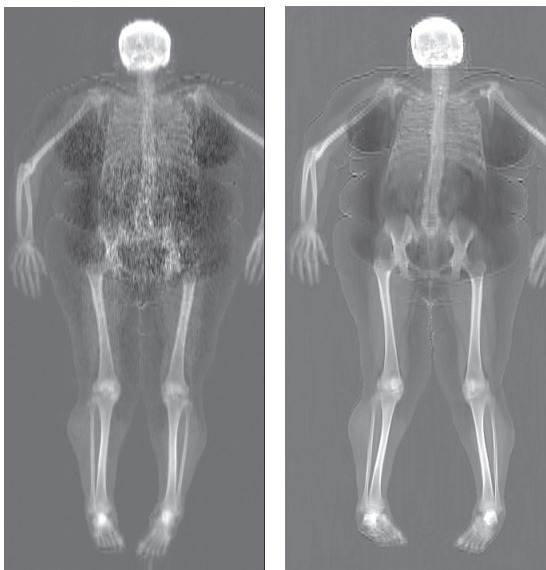


Figure 3

Same subject as above. Note the absence of noise in the abdominal region in the Horizon system exam on the right.

Hologic continues to place a premium on long-term stability and reliability. A patented internal reference system is employed – along with a full sized X-ray tube for dependability and long life. However, like the new X-ray generator, the internal reference system is now more flexible. The internal calibration system and energy filtration system are now independently controlled to facilitate future feature enhancements.

Continuity with previous platforms is also essential. Horizon™ systems have the same X-ray technique factors (dose, kVp, mA, filtration, source to detector distance, etc.) as Discovery™ and supports all the same scan modes. Not surprisingly, there is excellent clinical agreement with an $r^2 = 0.99$ between the Horizon and Discovery systems (see Figure 4)². In vivo AP Spine and Total Hip precision was better than 1% for a 10-second exam², clear evidence that Horizon system is the ideal platform for monitoring bone mineral density.

Horizon DXA System Exclusive Features:

SE Femur Exams are FDA cleared³ to visualize features associated with atypical femoral fractures, including the “dreaded black line.” Atypical femoral fractures are stress fractures associated with long-term antiresorptive therapy (e.g. bisphosphonate treatment), and are often bilateral. They typically develop over an extended period of time and are frequently associated with groin or leg pain^{4,5}. The FDA instructs physicians to evaluate bisphosphonate-treated patients who report new groin or leg pain for the presence of incomplete atypical femur fractures⁶.

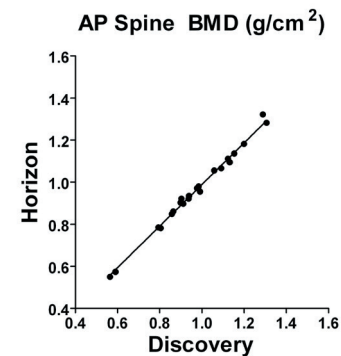
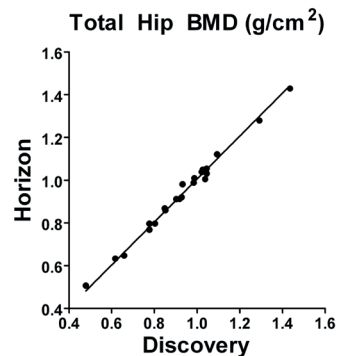


Figure 4



BMD correlation between Horizon and Discovery densitometers. Data courtesy of A. Myers and L. Jankowski. Illinois Bone and Joint Institute.

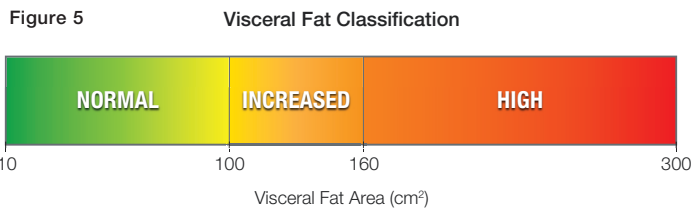
Incomplete atypical femur fractures often present as localized periosteal or endosteal cortical thickening along the lateral cortex of the femur. This focal thickening of the lateral cortex is sometimes accompanied by a transverse radiolucent line – referred to in the literature as the “dreaded black line” due to the poor prognosis associated with this feature. Nearly the entire femur should be evaluated, as atypical femur fractures can occur anywhere below the lesser trochanter to just proximal to the supracondylar flare. When focal cortical thickening is accompanied by a transverse radiolucent line, it is sometimes termed “beaking” due to its resemblance to a bird’s beak.

If a complete atypical femur fracture occurs, healing time is often delayed. A large retrospective study in Australia⁷ found that while atypical fracture patients tend to be younger and more active than non-atypical femur fracture patients, after an atypical femur fracture:

“Patients are hospitalized in acute care or rehab for an average of 21 days and our cohort experienced serious complications such as fat embolism. Self-reported health and function decreased post-operatively in a majority of patients.”

This study concluded that “Prescription of bisphosphonate therapy for osteoporosis should be accompanied by ongoing surveillance and warning of the possibility of atypical and minimal trauma fractures.”⁷

InnerCore™ is FDA cleared⁸ to estimate visceral adipose tissue (VAT) area from a whole body exam. VAT area, which is only available from Hologic, has been shown to predict mortality⁹ and above a threshold of 100 to 160 cm² (depending on gender and ethnicity) is associated with multiple cardiovascular disease (CVD) risk factors¹⁰.



Visceral fat thresholds associated with metabolic risk factors for coronary heart disease.^{10,12,13}

Over the last decade, obesity has exploded to epidemic proportions in many developed countries. Obesity-related health risks include coronary heart disease, type 2 diabetes, stroke, dyslipidemia and certain types of cancer. There is mounting evidence that distribution and type of excess fat may be an important prognostic indicator for disease risk. Unlike subcutaneous fat whose main function is energy storage, visceral fat cells are metabolically active and impact a wide variety of clinical risk factors, including fasting glucose levels, serum triglycerides, and cholesterol.¹¹

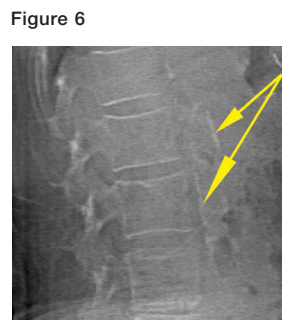
Visceral fat occurs within the envelope formed by the abdominal muscles, principally within the greater and lesser omentum that connects the abdominal organs, and in mesenteric fat. Visceral fat is most commonly measured in units of fat area (cm²). Previously, visceral fat area was typically measured from a CT slice centered at the L4/L5 juncture. By estimating the visceral fat area from DXA whole body scans, Hologic has significantly reduced the burden and radiation dose associated with obtaining this measurement.

Diagnostic thresholds for visceral fat area are becoming more firmly established. Depending on gender and ethnicity, the literature suggests a threshold of 100 to 160 cm² is associated with greater CVD risk factors^{10,12,13}

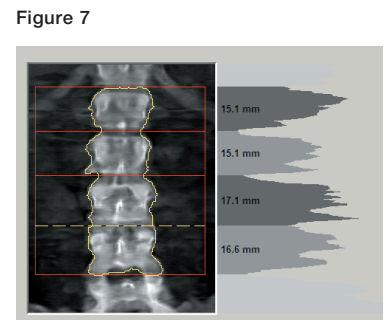
Abdominal Aortic Calcifications have been shown prospectively to predict myocardial infarction or stroke independent of traditional cardiovascular risk factors¹⁴.

Heart disease and stroke are the first and third leading causes of death in the United States. Atherosclerosis is the common pathological process underlying myocardial infarction, stroke and other occlusive vascular diseases. Because atherosclerosis has a long latent period between early phases of the disease and the manifestation of clinical symptoms, there is an opportunity for primary prevention if patients can be identified before the first clinical event. Unfortunately for many individuals the first manifestation of underlying disease is an unexpected acute myocardial infarction or sudden death. Two-thirds of women who die of cardiovascular events had no prior sign of the disease¹⁵.

Calcification of the abdominal aorta is a sub-clinical manifestation of atherosclerosis and can be detected during a 10-to-15 second single-energy lateral spine exam (IVA™ or IVA-HD) with Hologic densitometers. Only Hologic DXA scanners have received FDA clearance for this indication¹⁶.



Abdominal aortic calcification seen with an IVA exam.



Analysis screen of a BMI=47 obese patient showing histogramming feature.

Conclusion

Hologic first introduced dual-energy X-ray absorptiometry in 1987, setting the standard for skeletal health assessment. The innovation continues with the Horizon™ DXA system – a technologically advanced imaging system that empowers physicians to make more informed diagnosis and treatment decisions.

1. www.who.int/ipcs/features/cadmium.pdf. Exposure to cadmium: A major public health concern. (World Health Organization, 2010).
2. Preliminary data from A. Myers and L. Jankowski at Illinois Bone and Joint Institute. September 2013.
3. FDA 510K clearance K130277(2013).
4. Shane, E. et al. Atypical subtrochanteric and diaphyseal femoral fractures: Second report of a task force of the American Society for Bone and Mineral Research. *J Bone Miner Res* epub ahead of print May 28 (2013).
5. Shane, E. et al. Atypical subtrochanteric and diaphyseal femoral fractures: report of a task force of the American Society for Bone and Mineral Research. *J Bone Miner Res* **25**, 2267-94.
6. Safety update for osteoporosis drugs, b., and atypical fractures (FDA Drug Safety Communication [10-13-2010]).
7. Shkolnikova, J., Flynn, J. & Choong, P. Burden of bisphosphonate-associated femoral fractures. *ANZ J Surg* **83**, 175-81.
8. FDA 510K clearance K113356. (2011).
9. Kuk, J.L. et al. Visceral fat is an independent predictor of all-cause mortality in men. *Obesity (Silver Spring)* **14**, 336-41 (2006).
10. Katzmarzyk, P.T., Greenway, F.L., Heymsfield, S.B. & Bouchard, C. Clinical utility and reproducibility of visceral adipose tissue measurements derived from dual-energy X-ray absorptiometry in White and African American adults. *Obesity (Silver Spring)*.
11. Bergman, R.N. et al. Why visceral fat is bad: mechanisms of the metabolic syndrome. *Obesity (Silver Spring)* **14 Suppl 1**, 16S-19S (2006).
12. Hiuge-Shimizu, A. et al. Absolute value of visceral fat area measured on computed tomography scans and obesity-related cardiovascular risk factors in large-scale Japanese general population (the VACATION-J study). *Ann Med* **44**, 82-92.
13. Nicklas, B.J. et al. Visceral adipose tissue cutoffs associated with metabolic risk factors for coronary heart disease in women. *Diabetes Care* **26**, 1413-20 (2003).
14. Schousboe, J.T. et al. Abdominal aortic calcification detected on lateral spine images from a bone densitometer predicts incident myocardial infarction or stroke in older women. *J Bone Miner Res* **23**, 409-16 (2008).
15. Thom, T. et al. Heart disease and stroke statistics--2006 update: a report from the American Heart Association Statistics Committee and Stroke Statistics Subcommittee. *Circulation* **113**, e85-151 (2006).
16. FDA 510K clearance K060111. (2006).

hologic.com | info@hologic.com | +1.781.999.7300

North America / Latin America

35 Crosby Drive
Bedford, MA 01730-1401
USA

Europe

Everest (Cross Point)
Leuvensesteenweg 250A
1800 Vilvoorde
Belgium

Asia Pacific

7th Floor, Biotech Centre 2
No. 11 Science Park West Avenue
Hong Kong Science Park
Shatin, New Territories
Hong Kong

Australia

Suite 402, Level 4
2 Lyon Park Road
Macquarie Park NSW 2113
Australia